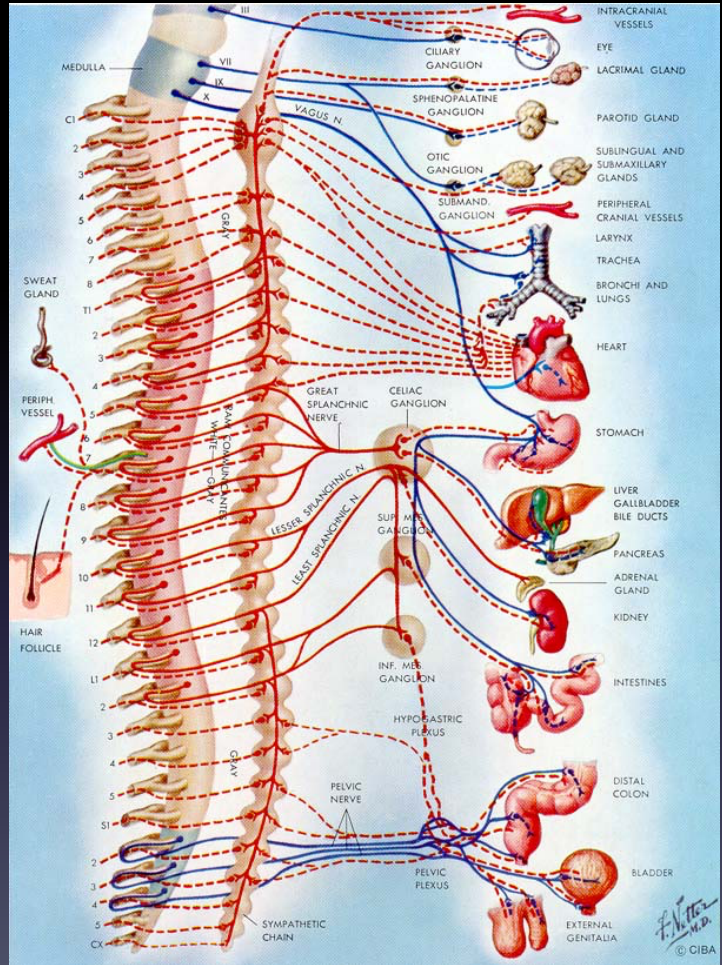
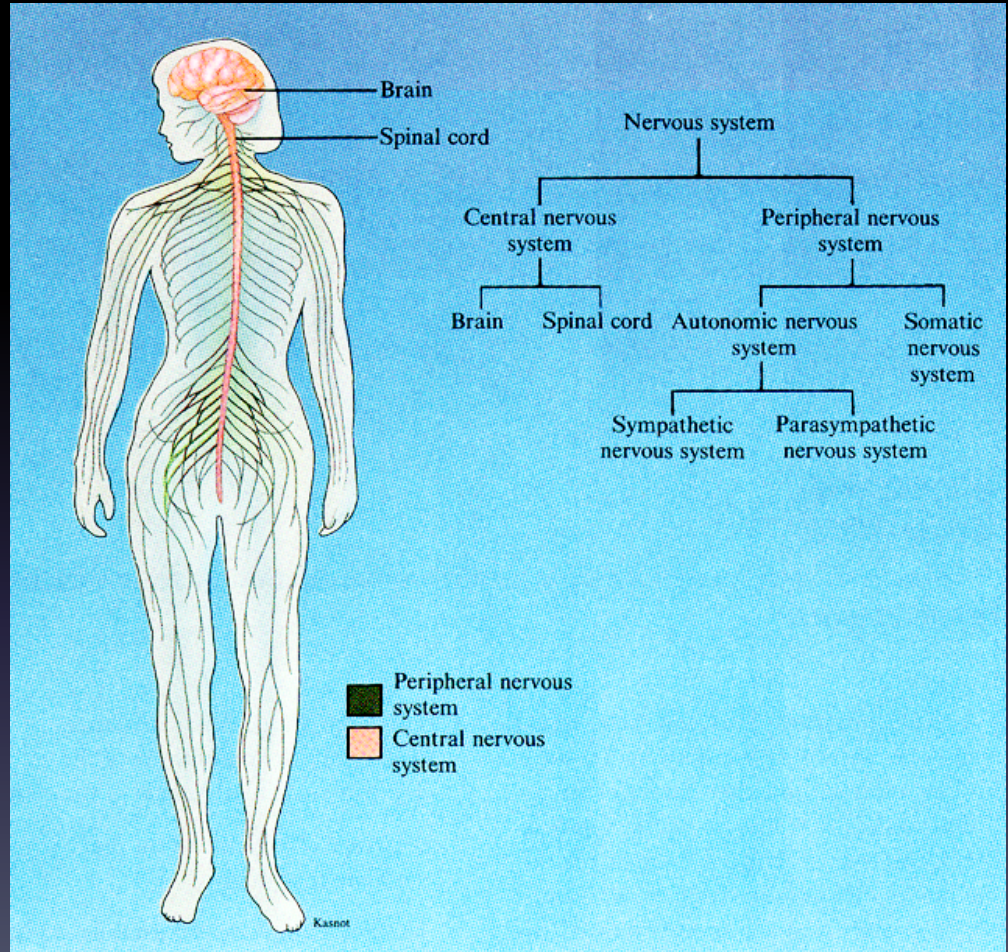


Review of the Autonomic Nervous System



CNS
=
BRAIN
+
SPINAL CORD



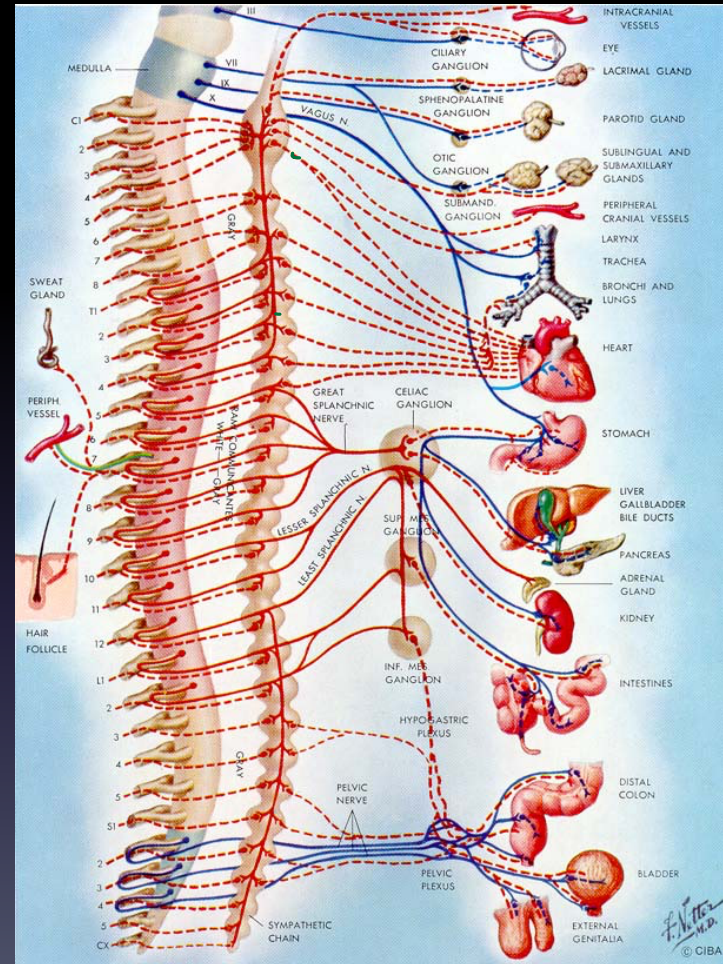
I. Peripheral Nervous System

a. Somatic Nervous System

b. Autonomic Nervous System

(1) Sympathetic Nervous System

(2) Parasympathetic Nervous System



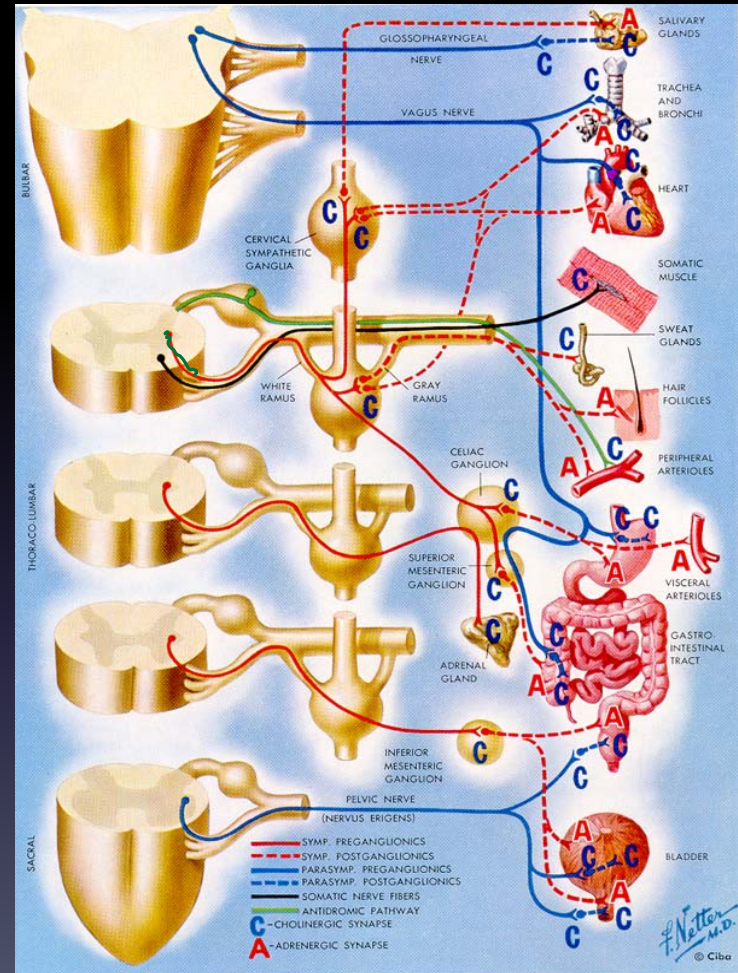
I. Peripheral Nervous System

a. Somatic Nervous System

b. Autonomic Nervous System

(1) Sympathetic Nervous System

(2) Parasympathetic Nervous System



CNS: Medulla Oblongata

II. Medulla Oblongata

- a. Cardiac Center
- b. Vasomotor Center
- c. Respiratory Center
- d. ARAS (ascending reticulating activating center)

